

PUBLICATIONS

*****CTSNet**

- Chen SA**, Titsworth M, Monaghan K, Yang B. Aortic Annular Enlargement: Why and How. *Annals of Thoracic Surgery*. 2024 (Invited Expert Review, pending)
- Makinejad A, Monaghan K, **Chen SA**, Wu X, Ling C, Kim K, Fukuhara S, Patel HJ, Pagani F, Deeb GM, Yang B. Aortic Annular Enlargement versus Isolated Aortic Valve Replacement in Patients with Matched Annulus. *Annals of Thoracic Surgery*. 2024 (Accepted, pending publication)
- Brescia AA, **Chen SA**, Monaghan K, Yang B. Aortic Annular Enlargement with Y-Incision/Rectangular Patch: Tips and Pitfalls. *Operative Techniques in Thoracic and Cardiovascular Surgery: A Comparative Atlas*. 2024. (Accepted, pending publication)
- Anderson D, **Chen SA**, Catrip JM, Kiaii. (2024). Chapter 7: Hybrid Coronary Revascularization. *Atlas of Cardiac Surgical Techniques*, 3e, by Sellke FW. Elsevier (Pending publication; ISBN 9780443118470)
- Dimagli A, Malas J, **Chen SA**, Sandner S, Schwann T, Tatoulis J, Puskas J, Bowdish ME, Gaudino M. Coronary Artery Aneurysms, Arteriovenous Malformations, and Spontaneous Dissections – A Review of the Evidence. *Annals of Thoracic Surgery*. 2023 Dec 9:S0003-4975(23)01249-3. doi: 10.1016/j.athoracsur.2023.11.033
- Chen SA**. The 10 Commandments of Building 3D-Printed Models for Surgical Simulation. *Innovations*. 2023;18(5):408-413. doi:10.1177/15569845231204233
- Xue AH, **Chen SA**, Ranade A, Smith K, Kasten J, Catrip JM, Kiaii B. How to implement a clinical robotic mitral valve surgery program. *Annals of Cardiothoracic Surgery*. 2022.11(5):504-509. doi: 10.21037/acs-2022-rmvs-14
- Anderson D, **Chen SA**, Southard J, Catrip JM, Kiaii, B. Multidisciplinary approach to coronary artery revascularization: optimal strategy for high-risk patients. *Journal of Cardiac Surgery*. 2022; 37:2900–2902. doi:10.1111/jocs.16685
- Sherazee EA, **Chen SA**, Li D, Li D, Frank P, Kiaii, B. Pain Management Strategies for Minimally Invasive Cardiothoracic Surgery. *Innovations*. 2022; 17(3), 167–176. doi:10.1177/15569845221091779
- Anderson D, **Chen SA**, Godoy LA, Brown LM, Cooke DT. Comprehensive Review of Chest Tube Management: A Review. *JAMA Surgery*. 2022; 157(3):269–274. doi:10.1001/jamasurg.2021.7050
- Firriolo JM, **Chen SA**, Wong GB. Craniopagus Separation using a Novel Tissue Expander Design. *Plastic and Reconstructive Surgery - Global Open*. 2021; 9(10S):65–66. doi:10.1097/01.GOX.0000799432.74728.03
- Guenther, TM, **Chen SA**, Gustafson JD, Ing FF, Brothers JA, Raff GW. Total anomalous origin of the coronary arteries from the pulmonary artery: a systematic review. *Cardiology in the Young*. 2021; 1-8. doi:10.1017/S1047951121002997.
- Theodorou CM, Trappey AF, **Chen SA**, McCracken K, Saadai P. Surgical Management of an Obstructive Müllerian Anomaly in a Patient with Anorectal Malformation. *Journal of Pediatric Surgery Case Reports*. Published online May 2021:101908. doi:10.1016/j.epsc.2021.101908.
- Guenther TM, Godoy LA, **Chen SA**, Rodriguez VM. Homograft aortic root replacement with modified Cabrol extension using cryopreserved femoral artery for bioprosthetic aortic valve endocarditis. *JTCVS Techniques*. 2020; 4:65-67. doi:10.1016/j.xjtc.2020.08.019.

- Guenther TM, **Chen SA**, Wozniack C, Leshikar D. Fatal cardiac injury sustained from an air gun: Case report with review of the literature. *International Journal of Surgery Case Reports*. 2020; 70:133-136. doi:10.1016/j.ijscr.2020.04.039.
- Singh GD, Rogers JH, **Chen SA**, Yap J, Smith TWR, Fan D, Stripe BR, Aman E. Adjunctive use of fluoroscopy during MitraClip implantation reduces procedural complexity: The Parallax Technique. *Catheterization and Cardiovascular Interventions*. 2020; 1-10. doi:10.1002/ccd.29323.
- Guenther TM, **Chen SA**, Balkhy HH, Kiaii B. Robotic Coronary Artery Bypass Grafting: The Whole 9 Yards. *Innovations (Phila): Technology and Techniques in Cardiothoracic and Vascular Surgery*. 2020; 15(3):204-210. doi:10.1177/1556984520922931.
- Yap J, **Chen SA**, Smith TWR, Rogers JH, Singh GD. Transjugular mitral valve repair with the MitraClip: A Step-by-step guide. *Catheterization and Cardiovascular Interventions*. 2020; 96:699-705. doi:10.1002/ccd.28902.
- Yap J, **Chen SA**, Stripe BR, Smith TWR, Rogers JH, Singh GD. Transseptal access for left heart structural interventions in the setting of prior atrial septal defect closure. *Catheterization and Cardiovascular Interventions*. 2020; 95(3):414-419. doi:10.1002/ccd.28548.
- Guenther TM, Godoy LA, **Chen SA**, Yeh J, Raff GW. Left ventricle to right atrial shunt associated with ventricular-atrial malalignment, double outlet right atrium, and subaortic membrane. *Seminars in Thoracic and Cardiovascular Surgery*. 2020; 32(1):140-142. doi:10.1053/j.semthor.2019.09.004
- Eng M, **Chen SA**, Southard JA, Smith TWR, Agrawal G, Wong G, Boyd WD, Low RI, Singh GD. Multi-pigtail technique is associated with decreased contrast use and fluoroscopic adjustment for transcatheter aortic valve replacement. *Structural Heart: The Journal of the Heart Team*. 2020; 4(2):131-138. doi:10.1080/24748706.2019.1682211.
- Chen SA**, Ong CS, Hibino N, Baschat AA, García JR, Miller JL. 3D printing of the fetal heart using 3D ultrasound imaging data. *Ultrasound in Obstetrics & Gynecology*. 2018; 52(6):808-809. doi:10.1002/uog.19166.
- Chen SA**, Ong CS, Malguria N, García JR, Vricella L, Hibino N. Digital design and 3D printing for surgical simulation and training of aortic arch reconstruction. *World Journal for Pediatric and Congenital Heart Surgery*. 2018; 9(4):454-458. doi:10.1177/2150135118771323.
- Chen SA**. (2018). Poster abstract: Designing customized 3D printed models for surgical planning in repair of congenital heart defects. *Journal of Biocommunication*, 42(1). <http://journals.uic.edu/ojs/index.php/jbc/article/view/9188/7512>.

PUBLISHED ILLUSTRATIONS IN JOURNAL ARTICLES, CHAPTERS, OTHERS

Louis C, Luc J, Wilder F, Hameed I, Blitzer D, Lin Y, Bhagat R. (2023). Thoracic Surgery Residents Association (TSRA) Operative Dictations in Cardiothoracic Surgery, 2e. **(Cover illustration)**

- Chen SA, Godoy LA. (2022).** Thoracic Surgery Residents Association (TSRA) Review of Cardiothoracic Surgery, 3e, edited by Brescia AA, Louis C. (**Chapter contents + Inside artwork**)
- Chapter 1: Thoracic and Pulmonary Anatomy
 - Chapter 42: Anatomy and Surgical Approaches to the Mediastinum
- Farmer D, Hirose S, Saadai P. Sabiston. (2021). Chapter 73: Fetal Surgery. Textbook of Surgery: The Biological Basis of Modern Surgical Practice, 21e. Elsevier Saunders. (**Inside artwork**).
- Guenther TM, Sherazee EA, Gustafson JD, Wozniak CJ, Brothers J, Raff GW. Anomalous Origin of the Circumflex or Left Anterior Descending Artery From the Pulmonary Artery. *World Journal for Pediatric and Congenital Heart Surgery*. 2020;11(6):765-775. doi: 10.1177/2150135120938705. (**Inside artwork**).
- Freischlag JA, Williams TK. (2019). Thoracic Outlet Syndrome. Current Surgical Therapy, 13e. Elsevier, 1038–1043. (**Inside artwork**).
- Freischlag JA, Orion KC. (2018). Venous Thoracic Outlet Syndrome. Current Management of Venous Diseases, 1e. Springer Science and Business Media, 363-370. (**Inside artwork**).
- Hadfield C, Clayton L. (2018). Clinical Guide to Fish Medicine. John Wiley & Sons, Inc. (**Inside artwork**).
- Qin EY, Cooper DD, Abbott KL, et al. Neural precursor-derived pleiotrophin mediates subventricular zone invasion by glioma. *Cell*. 2017; 170(5):845-59.e19. (**Cover illustration concept, graphical abstract, inside artwork**).
- Venkatesh H, Monje M. Neuronal activity in ontogeny and oncology. *Trends in Cancer*. 2017; 3(2):89-112 (**Inside artwork**).
- Transaxillary First Rib Resection for Thoracic Outlet Syndrome, for Johns Hopkins Heart and Vascular Institute. (2016).
www.hopkinsmedicine.org/heart_vascular_institute/conditions_treatments/conditions/thoracic_outlet_syndrome.html. (**Animation**). https://youtu.be/4ADbPso_vyM
- Demetriades D, Talving P, Inaba K. (2015). Blunt Thoracic Aortic Injury. Rich's Vascular Trauma, 3e. Elsevier, Inc., 100-112. (**Inside artwork**).
- Perry PA, Young N. Aortic root enlargement with ascending-to-descending aortic bypass in repair of coarctation. *Journal of Heart Valve Disease*. 2015; 24(4):516-8. (**Inside artwork**).
- Skora AD, Douglass J, Hwang MS, et al. Generation of MANAbodies specific to HLA-restricted epitopes encoded by somatically mutated genes. *Proceedings of the National Academy of Sciences USA*. 2015; 112(32):9967-72. (**Cover illustration, 2 versions**).
- Venkatesh HS, Johung TB, Caretti V, et al. Neuronal activity promotes glioma growth through neuroigin-3 secretion. *Cell*. 2015; 161(4):803-16. (**Graphical abstract, inside artwork**).
- Nerman M. (2014). Healing Pain and Injury. Bay Tree Publishing. (**160+ book illustrations**).
- Gibson EM, Purger D, Mount CW, et al. Neuronal activity promotes oligodendrogenesis and adaptive myelination in the mammalian brain. *Science*. 2014; 344(6183):1252304. (**Graphical abstract, inside artwork**).
- Hinck L. Tumor suppressors: heroes and villains. *Journal of Mammary Gland Biology and Neoplasia*. 2011; 16(3):169-71. (**Cover illustration**).

PRESENTATIONS & POSTERS

- 2024 **Chen SA.** (2024). The HeART of Surgery.
- Oral Presentation for Association of Medical Illustrators (AMI) Meeting, Rochester, NY, July 26, 2024
- 2024 Aribindi K, Addepalli S , Miller J , Adams JY, **Chen SA**, Evans SA, Kiaii B, Black HB. (2024). Veno-arterial Extracorporeal Membrane Oxygenation Complicated By Heparin Induced Thrombocytopenia And Use Of Hboc-201 In a Jehovah’s Witness Patient: A Novel Blood Preservation Technique
- **Poster Presentation** for American Thoracic Society Meeting, San Diego, CA, May 2024
- 2023 **Chen SA**, Catrip JM, Kiaii B. (2023). Use Of 3D Printed Ribcage Models to Investigate Ideal Intrathoracic Ratio For Robotic Left Internal Thoracic Artery Harvesting
- Oral Presentation for Association of Medical Illustrators (AMI) Meeting, Henderson, NV, July 22, 2023
- Oral Presentation for the International Society for Minimally Invasive Cardiothoracic Surgery (ISMICS) Annual Meeting, Boston, MA, June 1, 2023
- Oral Presentation for UC Davis Department of Surgery Research Day Symposium, Sacramento, CA, April 11, 2023
- 2022 Xue AH, **Chen SA**, Evans S, Raff GW, Kiaii B. (2022). Repair of Isolated Giant Right Coronary Artery Aneurysm
- Oral Presentation for International Coronary Congress (ICC), Tokyo, Japan, Dec 1, 2022
- 2022 Catrip JM, **Chen SA.** (2022). Advanced Therapies – Mechanical Circulatory Support
- Oral Presentation for UC Davis Heart Failure Summit, Sacramento, CA, October 29, 2022
- 2022 **Chen SA.** (2022). Craniopagus Twin Separation Guided by Novel Virtual and Physical Pre-Surgical Simulation
- Oral Presentation for Association of Medical Illustrators (AMI) Meeting, Des Moines, IA, July 22, 2022
- 2022 **Chen SA.** (2022). Art Not Just for Artists – Using Art & 3D Printing for Surgical Preparation
- Invited Oral Presentation for the International Society for Minimally Invasive Cardiothoracic Surgery (ISMICS) Annual Meeting, Warsaw, Poland, June 18, 2022
- 2022 Kiaii B, **Chen SA**, Anderson D. (2022). Hybrid Revascularization: How to Do It?
- Oral Presentation for STS Coronary Congress, Ottawa, ON, Canada, June 5, 2022
- 2022 Xue AH, **Chen SA**, Catrip JM, Kiaii B. (2022). How to implement a clinical robotic mitral valve surgery program.
- Keynote Lecture Series for Annals of Cardiothoracic Surgery, Virtual, May 2022
- 2022 Sherazee EA, Guenther TM, **Chen SA**, Kiaii B. (2022). Review of Graft Patency in Robotically Assisted Coronary Artery Bypass and Totally Endoscopic Coronary Bypass Surgery
- Oral Presentation at UC Davis Department of Surgery Research Day Symposium, Sacramento, CA, April 12, 2022
- Oral Poster Presentation at ISMICS Annual Meeting Poster Competition, Warsaw, June 18, 2022
- 2022 Kiaii B, **Chen SA**, Catrip JM. (2022). “Robotically assisted coronary bypass grafting – technical tips from expert surgeons”

- Webinar for ISMICS, Virtual, February 12, 2022
- 2022 Evans S, **Chen SA**. (2022). UC Davis COVID-19 ECMO Experience
 - Grand Rounds Presentation at UC Davis Health, Sacramento, CA, January 11, 2022
- 2021 **Chen SA**, Evans S, Catrip JM, Southard JA, Kiaii B. (2021). Optimal Planning in Multidisciplinary Approach for Hybrid Revascularization in a High-Risk Patient with High Grade Left Main Disease.
 - Poster Presentation for International Coronary Congress (ICC), New York City, NY, Dec 2021
- 2021 Chen L, **Chen SA**, Evans S, Catrip JM, Kiaii B, Kesarwani M, Singh GD, Southard JA, Stripe BR. (2021). LVOT Injury After Transcatheter Aortic Valve Replacement.
 - Oral Presentation for Transcatheter Cardiovascular Therapeutics (TCT), Orlando, FL, Nov 4, 2021
- 2021 Kiaii B, **Chen SA**. (2021). Robotic-Assisted Valvular Procedures.
 - Oral Presentation for ISMICS Workshop along with 5th Annual Conference of Society of Minimally Invasive Cardiovascular & Thoracic Surgeons of India (SMICTSI), Virtual, Sept 25, 2021
- 2021-2022 Wong GB, Firriolo JM, **Chen SA**. (2021). Craniopagus Separation Using a Novel Tissue Expander Design.
 - Invited Oral Presentation at Gary Lees Symposium, Johns Hopkins Department of Art as Applied to Medicine, Baltimore, MD, June 3, 2022
 - Oral Presentation at the 79th American Cleft Palate-Craniofacial Association (ACPA) annual meeting, Fort Worth, TX, April 2022
 - Invited Oral Presentation at the Lilliputian Surgical Society, Sacramento, CA, Sept 18, 2021
 - Invited Oral Presentation at California Society of Plastic Surgeons, Monterey, CA, May 29, 2021
 - Grand Rounds Presentation at UC Davis Health, Sacramento, CA, April 27, 2021
 - Oral Presentation at UC Davis Department of Surgery Research Day Symposium, April 20, 2021
- 2021 Sherazee EA, **Chen SA**, Sarkeshik AA, Guenther TM, Wozniak CJ, Raff GW (2021). Role of Extracorporeal Membrane Oxygenation for COVID-19 Associated Pulmonary Failure–Assessment of a Single Center Experience.
 - Poster Presentation for 18th Annual Perioperative and Critical Care Conference, STS, Sept 10, 2021
- 2021 Kiaii B, **Chen SA**, Evans S, Catrip JM. (2021). Hybrid Coronary Artery Revascularization: Optimal Strategy for High Risk Coronary Artery Disease Patients.
 - Oral Presentation for Encore Seoul, Virtual, Sept 9, 2021
- 2021 Kiaii B, **Chen SA**. (2021). Robotic-Assisted Cardiac Surgery.
 - Oral Presentation for FAH-SYSU & CITRUS Surgical Robotics Seminar 2, Virtual, August 25, 2021
- 2020 **Chen SA**, Guenther TM, Abazid R, Kiaii B. (2020). Do We Need Fancy Anatomic Imaging to Perform Robotic Coronary Surgery?
 - Online Curriculum for Robotic Cardiac Surgery, the Society of Thoracic Surgeons Summer 2020 (sts.org/roboticcardiac)
- 2020 **Chen SA**, Guenther TM, Abazid R, Kiaii B. (2020). Patency Outcomes for Robotic CABG.
 - Online Curriculum for Robotic Cardiac Surgery, the Society of Thoracic Surgeons Summer 2020 (sts.org/roboticcardiac)
- 2019 **Chen SA**. (2019). Utilizing Segmentation-based Cardiac Models for Clinical Education.
 - Oral Presentation at the Association of Medical Illustrators Conference, Milwaukee, WI, 2019

- 2019 **Chen SA**, Chen L, Smith T, Fan D, Stripe B, Boyd WD, Rogers JH, Singh GD. (2019). Adjunctive Use of Fluoroscopy during MitraClip Implantation to Minimize Clip Mal-rotation, Preserve Alignment, Reduce Number of Grasps and Need for Clip Eversion.
- Moderated Poster Presentation at Transcatheter Valve Therapies (TVT), Chicago, IL, 2019
- 2018 **Chen SA**, Ong CS, Hibino N, García JR, Baschat AA, Miller JL. (2018). 3D Printing of the Fetal Heart from Prenatal Ultrasound Derived Data.
- Abstract for scientific program at the 28th World Congress on Ultrasound in Obstetrics and Gynecology, Singapore, 2018.
- 2018 Eng M, Smith TW, Southard JA, Wong G, Stripe BR, Fan D, Choi J, **Chen SA**, Agrawal G, Rajpal G, Low R, Singh GD. (2018). Multi-Pigtail Technique Is Associated with Less Contrast Use and Fluoroscopic Adjustment in Determining Perpendicular Angle of Deployment for Transcatheter Aortic Valve Replacement.
- Poster Presentation at Transcatheter Valve Therapies (TVT), Chicago, IL, 2018
- 2018 Trivedi A, **Chen SA**, Thorsell E. (2018). Effects of A Novel Educational Outreach Intervention on Science Interest and Understanding among 8th grade Students in Sacramento.
- Poster Presentation at AOAlE, the annual AOA fundraiser, UC Davis School of Medicine, 2018.
- Poster Presentation at the Annual Medical Student Research Forum, UC Davis SOM, 2018.
- 2017-2018 **Chen SA**, Hibino N, García JR. (2017). Designing Customized 3D Printed Models for Surgical Planning in Repair of Congenital Heart Defects.
- Oral Presentation at the Congenital Heart Surgeons' Society Annual Meeting, Chicago, IL, 2017
- Oral Presentation at the Association of Medical Illustrators Conference, Austin, TX, 2017
Invited to speak as the Alan Cole Scholar; also presented a poster at the AMI Conference
- Poster Presentation at the Annual Medical Student Research Forum, UC Davis SOM, 2018.
- Poster Presentation at Materialise 3D Printing in Medicine Conference, Plymouth, MI, 2017
- 2015 **Chen SA**, Lankford L, Pivetti C, Farmer D, Wang A. (2015). Effects of Placenta-derived Mesenchymal Stromal Cell Secretome on Postmitotic Developing Neurons.
- Poster Presentation at the Annual Medical Student Research Forum, UC Davis SOM, 2015
-

Comprehensive Review of Chest Tube Management A Review

Devon Anderson, MD; Sarah A. Chen, MD, MA; Luis A. Godoy, MD; Lisa M. Brown, MD, MAS; David T. Cooke, MD

IMPORTANCE Thoracostomy, or chest tube placement, is used in a variety of clinical indications and can be lifesaving in certain circumstances. There have been developments and modifications to thoracostomy tubes, or chest tubes, over time, but they continue to be a staple in the thoracic surgeon's toolbox as well as adjacent specialties in medicine. This review will provide the nonexpert clinician a comprehensive understanding of the types of chest tubes, indications for their effective use, and key management details for ideal patient outcomes.

OBSERVATIONS This review describes the types of chest tubes, indications for use, techniques for placement, common anatomical landmarks that are encountered with placement and management, and an overview of complications that may arise with tube thoracostomy. In addition, the future direction of chest tubes is explored, as well as the management of chest tubes during the COVID-19 pandemic.

CONCLUSIONS AND RELEVANCE Chest tube management is subjective, but the compilation of data can inform best practices and safe application to successfully manage the pleural space and ameliorate acquired pleural space disease.

JAMA Surg. 2022;157(3):269-274. doi:10.1001/jamasurg.2021.7050
Published online January 26, 2022.

Author Affiliations: Division of General Thoracic Surgery, Department of Surgery, University of California, Davis Health, Sacramento.

Corresponding Author: David T. Cooke, MD, University of California, Davis Health, 2335 Stockton Blvd, North Addition Office Building, Ste 6121, Sacramento, CA 95817-2214 (dtcooke@ucdavis.edu).

Thoracostomy tube, otherwise known as chest tube, insertion can be traced back to the fifth century BCE when Hippocrates described using a hollow tin tube to drain what was likely an empyema.¹ In 1889, valved tubes with air-tight seals were first reported to prevent outside atmospheric pressure from collapsing the lung on inspiration.² In 1922, chest tubes were first documented in the postoperative care of patients undergoing modern thoracic surgery.³ They were used throughout World War II to restore lung function after traumatic thoracotomies, were used during the Korean War, and later became the standard of care for drainage of the pleural space for trauma during the Vietnam War.⁴ Chest tubes and their management continue to evolve and are modified to fit modern needs, including clinical conditions associated with the COVID-19 pandemic.

Indications

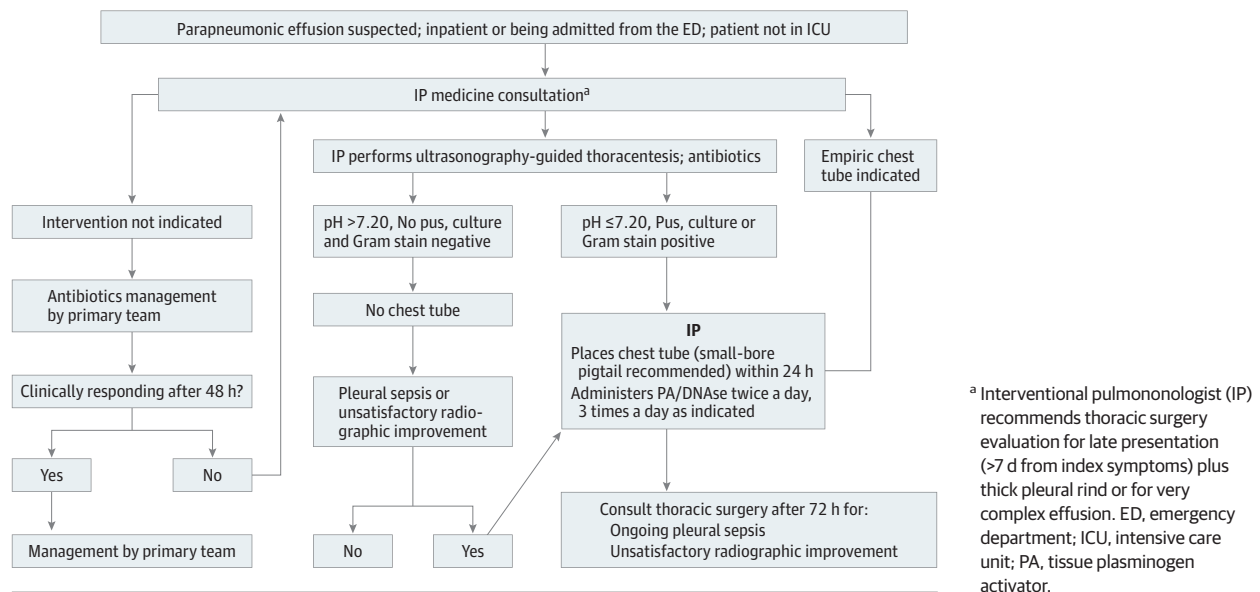
The potential space between the visceral pleura that envelops the lungs and the parietal pleura covering the chest wall, diaphragm, and mediastinum is the pleural cavity, which contains lubricating pleural fluid secreted by the parietal pleural capillaries. Air and abnormal fluid can accumulate in this space, causing mass effect and disruptions in the normal negative intrathoracic pressure.

When air fills the pleural cavity, it is called a pneumothorax, which is further categorized according to its etiology as primary spontaneous, secondary spontaneous, or traumatic.⁵⁻⁷ Chest tubes are used to evacuate air in the pleural cavity and reestablish the negative in-

trathoracic pressure, allowing the lung to reexpand and restore physiologic ventilation and cardiac function.⁶⁻⁹ A tension pneumothorax develops when air enters on inspiration and is unable to escape on expiration. This leads to effective mass effect on intrathoracic structures, such as the lung itself; mediastinal structures, such as the venae cavae; and cardiac chambers, resulting in hemodynamic compromise from restricted venous return and cardiac output. This is a medical emergency and should initially be managed with immediate needle thoracostomy to decompress trapped and expanding pleural air before the placement of a formal chest tube.

Chest tubes are also used to evacuate excessive fluid from the pleural cavity, which is known as a pleural effusion. When there is pus in the pleural cavity, then it is considered an empyema. There are several ways to evacuate fluid from the pleural cavity and chest tubes are only one of the many options. A Cochrane review from 2017¹⁰ compared the surgical option of video-assisted thoracic surgery (VATS) with chest tube drainage of pleural empyema and found no difference in mortality or complications between the groups, but early VATS reduced the hospital length of stay. VATS has been considered the first-line treatment for retained hemothorax and empyemas with other modalities, such as intrapleural lytic therapy, reserved for poor operative candidates or as a second line treatment.¹¹ However, a meta-analysis by Hendriksen et al¹¹ found that treating retained hemothorax with lytic therapy rather than VATS allowed for an overall operative avoidance rate of 87% (95% CI, 81%-92%), with no heterogeneity in the pooled studies ($Q = 10.2$; $df = 9$; $P = .33$; $I^2 = 15.07\%$). The type of intrapleural lytic treatment is also important as Hendriksen et al¹¹ found that using tissue plasminogen acti-

Figure 1. Parapneumonic Effusions: University of California, Davis, Pulmonary and General Thoracic Surgery Management Pathway



vator (t-PA) as the lytic agent allowed for a favorable number of patients to avoid surgical intervention compared with other lytic agents. The combination of t-PA and dornase (DNase) was associated with a 60% reduction in pleural fluid collection as seen on imaging and with a significant reduction in pleural opacity, compared with placebo in the randomized clinical trial by Rahman et al.¹² When t-PA and DNase were used on their own as opposed to in combination, this study did not find a significant reduction in the pleural fluid collection compared with placebo.¹² The evidence supports combining t-PA and DNase for intrapleural lytic therapy. Given the effectiveness of treating early-phase empyema with a chest tube and intrapleural use of t-PA and DNase, as well as the use of VATS to reduce length of hospital stay, the authors developed a multidisciplinary protocol with general thoracic surgery and interventional pulmonary medicine for the algorithmic care of patients presenting with empyema, starting with a small-bore chest tube placement followed by intrapleural use of t-PA and DNase. If this initial step is unsuccessful, the next stage of the pathway is thoracic surgical consultation for VATS decortication (Figure 1).

Types of Chest Tubes

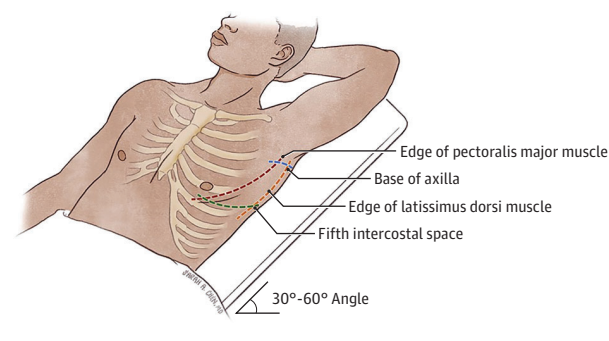
Chest tubes come in a variety of sizes and materials to best suit the clinical needs of the patient. In the US, they are generally measured by the internal diameter of the tube in units of French. One increment of the French scale is equal to a one-third-millimeter diameter, (eg, 24F is equal to an 8-mm caliber). By most prevalent convention, a tube of 20F or larger is considered a large-bore chest tube and a tube less than 20F tube is considered a small-bore chest tube, although there are some studies that define a large-bore chest tube as larger than 14F.^{5,13,14} A common type of small-bore chest tube is a pigtail catheter, named because the tip coils at the end like a pig's tail to prevent dislodgment.¹³

Small-bore chest tubes are used as the first-line treatment for pneumothorax, transudative pleural effusions, and simple empyemas, whereas large-bore chest tubes are often necessary for more viscous disease processes, such as a hemothorax and complex exudative effusions and empyemas.^{13,15} A meta-analysis by Chang et al⁵ demonstrated that small-bore chest tubes are associated with lower complications rates and shorter drainage duration and hospital stay compared with large-bore chest tubes. A randomized clinical trial by Hussain et al¹⁶ identified similar findings of a reduction in drainage duration and hospital stay with small-bore pigtail catheters compared with large-bore chest tubes in patients with secondary spontaneous pneumothorax. The most prominent advantage of a small-bore chest tube is its size, which allows for a smaller incision and decreased pain experienced by the patient.^{16,17} The randomized clinical trial by Kulvatunyou et al¹⁷ demonstrated a lower pain score in individuals with a pigtail catheter compared with a large-bore chest tube for traumatic pneumothorax. However, the small diameter of small-bore chest tubes may come at the cost of inefficient flow, as per Poiseuille's law ($\Delta P = 8\mu LQ/\pi R^4$, where Δp is change in pressure, μ is viscosity, Q is flow and R is radius) the decreasing radius of small-bore chest tubes can lend to a lower flow rate, which is the reason large-bore chest tubes are necessary in conditions that would otherwise clog a smaller tube, such as high-viscosity (μ) fluid.^{5,13,15}

Insertion

The placement of a chest tube is important and is performed by many different specialties in various settings. The ideal point of insertion is through an external landmark space known as the triangle of safety (Figure 2), which is bordered by the edge of the latissimus dorsi muscle, pectoralis major muscle, the base of the axilla, and transverse to the nipple line or inframammary fold, at or above the fifth

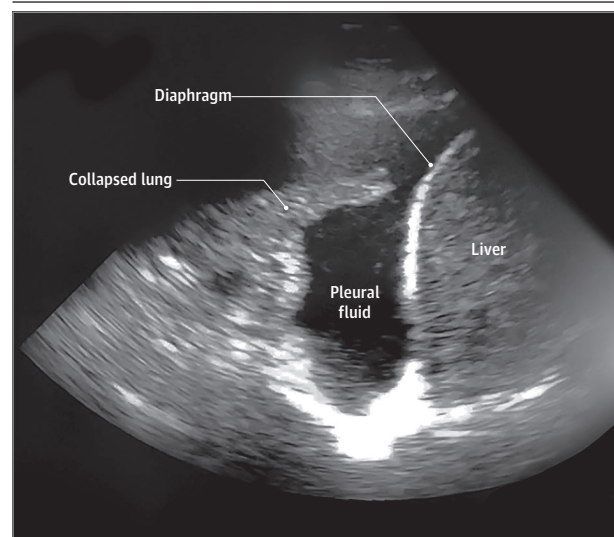
Figure 2. Triangle of Safety for Chest Tube Placement



intercostal space.^{13,14,18-20} However, placement of chest tubes is also influenced by the indication. For an apical pneumothorax, a chest tube can be placed in the second intercostal space in the midclavicular line, although less comfortable for the patient, and adequate drainage of an unclotted pneumothorax can be performed via lateral insertion at the fifth intercostal space.^{14,18} If the tube is placed in the triangle of safety, it is important to place it in a line anterior to the anterior superior iliac spine. Placing in the tube in a line behind this surface landmark may cause the patient to lie on the tube when in the supine position and mechanically occlude the tube. For a pleural effusion, a lower intercostal space may be used for insertion but special care must be taken to avoid penetrating the diaphragm, and subsequently the liver on the right and spleen and bowel on the left.¹³

The 3 ways to insert a chest tube are dissective, Seldinger (often ultrasonography guided), and the trocar technique, again often ultrasonography guided.^{13,14,19,20} Ultrasonography can be an invaluable tool to safely identify internal landmarks for chest tube placement. Figure 3 presents a representative sonographic image demonstrating the target abnormal collection of pleural fluid, in the right chest, for chest tube drainage, and adjacent structures of atelectatic lung, diaphragm and liver. Figure 4A highlights an important step for chest tube placement, which is using a finder needle (often a syringe with local anesthetic) just above the target rib to avoid the intercostal neurovascular bundle and aspirating the pleural space to confirm the location of the pleural pathology. For dissective insertion, a 1- to 2-cm incision is made overlying the rib of choice (the authors do not tunnel to a rib above), a Schnidt tonsil clamp is used to bluntly dissect through the subcutaneous tissue, the 3 muscular layers of the intercostal space (ie, the external intercostal muscle, the internal intercostal muscle, and innermost intercostal muscle), transthoracic fascia, and the parietal pleura until the clamp enters the pleural cavity. When attempting to enter the fifth intercostal space, it is important to dissect not perpendicular to the chest wall, but generally posterior and apical, the direction that most tubes should be placed (Figure 4B). Dissecting perpendicular to the chest wall and into the fifth intercostal space can lead to the tube heading directly into the oblique fissure, and then be entrapped by the subsequent expanded lung, rendering the tube ineffective after lung expansion. After successful spreading into the pleura space, a finger is used to confirm entry into the pleural space and the presence of adhesions. Adhesions are not bluntly broken with the finger, as pleural adhesions are often vascular and blunt dissection can

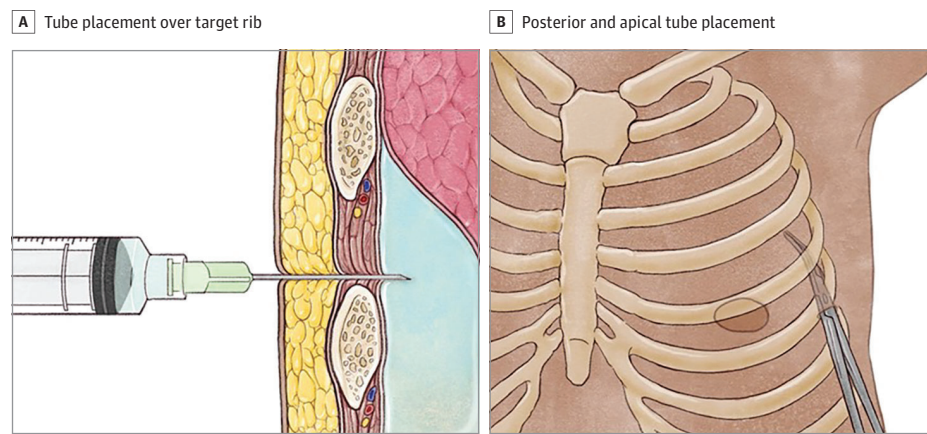
Figure 3. Representative Sonographic Image Demonstrating the Target Abnormal Collection of Pleural Fluid



lead to small vessel disruption and subsequently hemothorax.^{13,14} The Seldinger technique uses guidewires and tract dilators to assist the tube into the pleural cavity, all under ultrasonography guidance.^{19,21} Lastly, the trocar method may be used; however, it is associated with more complications owing to the rigid tip of the trocar causing intrathoracic injuries and has subsequently fallen out of favor for chest tube insertion.^{19,20,22} Regardless of the insertion technique, the chest tube needs to be advanced on the superior edge of the rib to avoid the neurovascular bundle bordering the rib above.^{13,14} It should also be positioned posteriorly and advanced until the tip is in a posteroapical location. The tube should also be fully inserted to ensure that the most proximal (sentinel) hole is within the pleural space to allow the chest tube to function properly.¹⁴ Lastly, it is important to secure the chest tube with a suture to prevent it from falling out. Most tubes can be removed without suture skin closure, but in children and adults with very low body mass index (calculated as weight in kilograms divided by height in meters squared), placement of an untied adjunctive chest tube suture at the time of insertion allows for closure of skin defects at the time of tube removal, especially large-bore tubes, to prevent entraining atmospheric air with tube removal.

Management

Once a chest tube is placed, it is connected to a drainage device, which, like the chest tube itself, has evolved over the years. The first rendition was a 1-compartment system reported by Playfair²³ in 1875, which used a 1-way valve to allow air to egress from the pleural cavity during expiration without returning on inspiration. In 1926, Lilienthal²⁴ developed a 2-compartment system, which allowed the accumulation of fluid in the first collection bottle without compromising the efficiency of the system and its ability to drain, as would have been observed in the first model. Then, the 3-compartment system emerged in 1952 with Howe, which allowed collection, water sealing, and suction and manometer capabilities that are combined into a single pleural drainage unit (PDU).^{19,25} This forms the

Figure 4. Insertion Technique

foundation of the modern PDU devices today, some of which are digitally operated.

Once placed, chest tubes may be attached to a PDU and set to active suction or to water seal, which is simple dependent drainage. The phrase “place a chest tube on water seal” is a misnomer, as modern PDUs have a constitutive water seal chamber that serves as a 1-way valve, preventing air from returning into the pleural space; placing a chest tube on water seal simply means taking the tube off active suction. The randomized clinical trial by Cerfolio et al²⁶ found that water sealing the chest tube on postoperative day 2 after thoracic surgery resulted in a significant resolution of small air leak the following day, with the authors noting that large air leaks do not benefit from water sealing. Another randomized clinical trial²⁷ demonstrated similar results of a shorter duration of air leak with early water sealing for postthoracic surgery chest tubes, which subsequently decreased the duration the chest tube was needed. Both of these studies, albeit randomized clinical trials, are limited by their small sample sizes. Brunelli et al²⁸ performed a randomized clinical trial with a larger sample size, did not find an advantage with water seal over suction for postthoracic surgery patients and the authors favor a hybrid approach of moderate suction overnight and water sealing during the day to allow for mobilization of the patient. The systematic review and meta-analysis by Coughlin et al²⁹ determined that there was no advantage of suction over water seal after thoracic surgery, with the exception of suction being superior to water seal in preventing a radiographic identification of pneumothoraces.

For patients with a traumatic chest injury, the systemic review and meta-analysis by Feenstra et al⁹ demonstrated evidence that favors low-pressure suction over water seal. This meta-analysis is limited in the number of studies, and therefore patient sample size, included. In addition, there are few patients with chest tubes in the setting of mechanical ventilation included in this study, which is an important subset of trauma patients. Patients who have an occult pneumothorax and are receiving positive pressure mechanical ventilation are at risk of developing a tension pneumothorax, therefore it may be necessary for a chest tube to be placed on suction in this subset of patients.³⁰ Overall, the management of a chest tube depends on the indication for insertion with evidence favor-

ing suction over water seal for both postthoracic surgery patients and traumatic chest injury patients, until resolution of air leak.

Removal

There are many factors that come into play when determining the correct time to remove a chest tube. The quality of the fluid should be free of chyle, or blood suggestive of active bleeding, and be nonpurulent.^{31,32} However, the quantity of fluid that is acceptable before the removal of a chest tube is without consensus, with varying recommended volume thresholds ranging from 200 mL per day to 500 mL per day.³¹⁻³³ Cerfolio et al³² performed a retrospective cohort analysis that demonstrated that chest tube removal up to 450 mL per day was acceptable in patients who underwent elective pulmonary resection. They reported that 364 of 1988 patients (18%) were able to go home sooner owing to surgeons changing to the higher threshold (450 mL per day) and only 11 patients (0.55%) were readmitted as a result of a recurrent symptomatic effusion. Grodzki et al³⁴ tested this conclusion a year later and removed chest tubes at the higher threshold of 450 mL per day and found that 6 of 40 patients (15%) were readmitted with pleural effusions, thus leading the authors to revert to their original practice of following a threshold of 200 mL per day for chest tube removal. The limitation in the former study is the lack of reliable follow-up, which could account for the low readmission rate, and the limitation in the latter study is the small sample size. Larger randomized clinical trials would be helpful in clarifying this gap in our understanding.

Whether to remove the chest tube at the end of expiration or inspiration is another question that has been widely debated. Novoa et al³¹ recommended removing the chest tube at the end of expiration during a Valsalva maneuver, which corresponds to the time when the difference between the atmospheric pressure and pleural pressure is at its lowest.³¹ Other studies, such as French et al,³⁵ emphasized the importance of a Valsalva maneuver during chest tube removal regardless of the respiratory phase in which it is removed. The chest tube should be removed swiftly and the defect in the chest wall should be closed with either a suture that was placed at the time of chest tube placement or with a properly occlusive dressing.

Complications

The retrospective review by Platnick et al³⁶ found that certain risk factors, such as chest tube placement in the emergency department, placement by emergency medicine clinicians, and placement in patients with a body mass index greater than 30 were all associated with chest tube complications. However, the exact complication rate associated with chest tubes is variable and has been quoted as high as 40%.³⁶⁻³⁸ The variability in the reported complication rate can be attributed to a lack of a universally accepted way to categorize the many different complications. Aho et al²⁰ proposed a way to standardize the reporting of complications surrounding chest tubes to allow for easier recording and collection of data. The 5 complication categories proposed were insertional, positional, removal, infectious, and malfunction. Insertional complications include injury to intrathoracic or extrathoracic organs within 24 hours of insertion, which is a complication most common with chest tubes being inserted via the trocar technique.^{19,20} Positional complications are defined as occurring 24 hours after insertion, including erosions into adjacent organs or any tube kinking, obstruction, or being entrapped in the fissure after lung expansion.^{19,20} Removal complications encompass failure to seal the chest defect after the chest tube is removed, resulting in entraining atmospheric air, or the retention of any foreign objects after removal.²⁰ Infectious complications involve any infection, either external from improper sterilizing techniques or internal with the development of an empyema.²⁰ Malfunction complications include problems that may arise from the health care clinician managing the chest tube or equipment issues.²⁰ Defining complications in these distinct categories allows clinicians to create a foundation to compare data collected in future studies and protocols to reduce the risk of complication associated with chest tubes.

COVID-19

Chest tube management during the COVID-19 pandemic, or any future coronavirus or H1N1 pandemic, is challenging owing to the risk of aerosolizing dangerous virions. Proper personal protective equipment, minimizing water seal, and using filters to decrease the number of aerosolized particles escaping into the air are modifications that have been implemented in many intensive care units around the world.^{37,39} A small observational cohort study⁴⁰ found that connecting 2 closed underwater drainage systems in series with an air filter attached to the second system was associated with a decrease in the dissemination of coronavirus particles, as evidenced by a lack of COVID-19 infection reported in their health care workers during the study. However, this study was limited with its small power.

ARTICLE INFORMATION

Accepted for Publication: October 22, 2021.

Published Online: January 26, 2022.
doi:10.1001/jamasurg.2021.7050

Conflict of Interest Disclosures: Dr Brown reported grants from National Institutes of Health

during the conduct of the study. No other disclosures were reported.

REFERENCES

1. Hippocrates. *The Genuine Works of Hippocrates*. Adams F, trans-ed. Sydenham Society; 1849.

2. Williams W. Treatment of empyema by a valvular tube hermetically sealed to the chest. *Br Med J*. 1889;1(1481):1107-1108. doi:10.1136/bmj.1.1481.1107

3. Lilienthal H. Resection of the lung for suppurative infections with a report based on 31 operative cases in which resection was done or

Future Directions

More recent studies are leaning toward conservative management in some specific pleural disease processes. The randomized clinical trial by Halifax et al⁴¹ demonstrated that the use of ambulatory devices for the treatment of primary spontaneous pneumothorax compared with usual care, which included aspiration or chest tube insertion, was associated with a significantly shorter hospital length of stay. These findings suggest that this subset of patients can be treated in an outpatient setting and that ambulatory devices should be considered as an effective treatment strategy for this disease process. However, there was an increase in the number of adverse events associated with the treatment with ambulatory devices, including enlarging pneumothorax and problems associated with the device, such as kinking or dislodgement, which will require more research if this approach is going to replace the current standard of care.

In a study by Brown et al,⁴² conservative treatments, such as observation of moderate- to large-sized primary spontaneous pneumothorax, were found to be noninferior to the placement of a small-bore chest tube regarding resolution of the pneumothorax within 8 weeks. The study reports that 118 of 125 patients (94%) of patients undergoing conservative management did not require an invasive procedure, thus challenging the paradigm that all patients with a hemodynamic and respiratory stable primary pneumothorax should routinely undergo decompression with a chest tube as the first treatment option.

The routine placement of a chest tube after thoracic surgery is another area with emerging research. The randomized clinical trial by Zhang et al⁴³ showed that the placement of a novel air-extraction double-lumen catheter was noninferior to the placement of a traditional chest tube in the incidence of a pneumothorax on postoperative day 1. The use of this air-extraction catheter was also associated with a significantly lower patient-reported pain score, which supports the argument that more conservative techniques can be used to optimize patient comfort without compromising clinical outcomes.

Conclusions

With the advancement of technology and the push toward less invasive approaches, the treatment of pleural conditions that were once managed solely by chest tubes continues to evolve. However, chest tubes are likely to continue to be a vital part of a clinician's repertoire as they are still considered the standard of care for certain pleural disease processes and life-saving devices in others. It is imperative that trainees have a solid foundation on the management of chest tubes, as their use is a dynamic process that will continue to change as time progresses. This review highlights the studies that have shaped the way chest tubes are managed today and allows the reader to develop and cultivate their understanding.

- intended. *Ann Surg.* 1922;75(3):257-320. doi:10.1097/0000658-192203000-00001
4. Monaghan SF, Swan KG. Tube thoracostomy: the struggle to the "standard of care". *Ann Thorac Surg.* 2008;86(6):2019-2022. doi:10.1016/j.athoracsur.2008.08.006
 5. Chang S-H, Kang Y-N, Chiu H-Y, Chiu Y-H. A systematic review and meta-analysis comparing pigtail catheter and chest tube as the initial treatment for pneumothorax. *Chest.* 2018;153(5):1201-1212. doi:10.1016/j.chest.2018.01.048
 6. Graham EA, Bell RD. Open pneumothorax: its relation to the treatment of empyema. *Am J Med Sci.* 1918; 156 (6): 839-871. doi:10.1097/00000441-191812000-00007
 7. MacDuff A, Arnold A, Harvey J; BTS Pleural Disease Guideline Group. Management of spontaneous pneumothorax: British Thoracic Society pleural disease guideline 2010. *Thorax.* 2010;65(suppl 2):ii18-ii31. doi:10.1136/thx.2010.136986
 8. Wolcott MW, Shaver WA, Jennings WD. Spontaneous pneumothorax. Management by tube thoracostomy and suction. *Dis Chest.* 1963;43(1):78-81. doi:10.1378/chest.43.1.78
 9. Feenstra TM, Dickhoff C, Deunk J. Systematic review and meta-analysis of tube thoracostomy following traumatic chest injury; suction versus water seal. *Eur J Trauma Emerg Surg.* 2018;44(6):819-827. doi:10.1007/s00068-018-0942-7
 10. Redden MD, Chin TY, van Driel ML. Surgical versus non-surgical management for pleural empyema. *Cochrane Database Syst Rev.* 2017;3(3):CD010651. doi:10.1002/14651858.CD010651.pub2
 11. Hendriksen BS, Kuroki MT, Armen SB, Reed MF, Taylor MD, Hollenbeak CS. Lytic therapy for retained traumatic hemothorax: a systematic review and meta-analysis. *Chest.* 2019;155(4):805-815. doi:10.1016/j.chest.2019.01.007
 12. Rahman NM, Maskell NA, West A, et al. Intrapleural use of tissue plasminogen activator and DNase in pleural infection. *N Engl J Med.* 2011;365(6):518-526. doi:10.1056/NEJMoa1012740
 13. Cooke DT, David EA. Large-bore and small-bore chest tubes: types, function, and placement. *Thorac Surg Clin.* 2013;23(1):17-24. v. doi:10.1016/j.thorsurg.2012.10.006
 14. Filosso PL, Guerrero F, Sandri A, et al. Errors and complications in chest tube placement. *Thorac Surg Clin.* 2017;27(1):57-67. doi:10.1016/j.thorsurg.2016.08.009
 15. Liu Y-H, Lin Y-C, Liang S-J, et al. Ultrasound-guided pigtail catheters for drainage of various pleural diseases. *Am J Emerg Med.* 2010;28(8):915-921. doi:10.1016/j.ajem.2009.04.041
 16. Hussein RMM, Elshahat HM, Shaker A, Hashem AZA. Study of pigtail catheter and chest tube in management of secondary spontaneous pneumothorax. *Egypt J Chest Dis Tuberc.* 2017;66(1):107-114. doi:10.1016/j.ejcd.2016.08.011
 17. Kulvatunyou N, Erickson L, Vijayasekaran A, et al. Randomized clinical trial of pigtail catheter versus chest tube in injured patients with uncomplicated traumatic pneumothorax. *Br J Surg.* 2014;101(2):17-22. doi:10.1002/bjs.9377
 18. Venuta F, Diso D, Anile M, Rendina EA, Onorati I. Chest tubes: generalities. *Thorac Surg Clin.* 2017;27(1):1-5. doi:10.1016/j.thorsurg.2016.08.001
 19. Munnell ER. Thoracic drainage. *Ann Thorac Surg.* 1997;63(5):1497-1502. doi:10.1016/S0003-4975(97)00082-9
 20. Aho JM, Ruparel RK, Rowse PG, Brahmabhatt RD, Jenkins D, Rivera M. Tube thoracostomy: a structured review of case reports and a standardized format for reporting complications. *World J Surg.* 2015;39(11):2691-2706. doi:10.1007/s00268-015-3158-6
 21. Seldinger SI. Catheter replacement of the needle in percutaneous arteriography; a new technique. *Acta radiol.* 1953;39(5):368-376. doi:10.3109/00016925309136722
 22. John M, Razi S, Sainathan S, Stavropoulos C. Is the trocar technique for tube thoracostomy safe in the current era? *Interact Cardiovasc Thorac Surg.* 2014;19(1):125-128. doi:10.1093/icvts/ivw071
 23. Playfair WS. Thoracocentesis in empyema. *Br Med J.* 1872;1(593):498-498. doi:10.1136/bmj.1.593.498-a
 24. Lilienthal H. *Thoracic Surgery.* Saunders; 1926.
 25. Toth JW, Reed MF, Ventola LK. Chest tube drainage devices. *Semin Respir Crit Care Med.* 2019;40(3):386-393. doi:10.1055/s-0039-1694769
 26. Cerfolio RJ, Bass C, Katholi CR. Prospective randomized trial compares suction versus water seal for air leaks. *Ann Thorac Surg.* 2001;71(5):1613-1617. doi:10.1016/S0003-4975(01)02474-2
 27. Marshall MB, Deeb ME, Bleier JIS, et al. Suction vs water seal after pulmonary resection: a randomized prospective study. *Chest.* 2002;121(3):831-835. doi:10.1378/chest.121.3.831
 28. Brunelli A, Monteverde M, Borri A, et al. Comparison of water seal and suction after pulmonary lobectomy: a prospective, randomized trial. *Ann Thorac Surg.* 2004;77(6):1932-1937. doi:10.1016/j.athoracsur.2003.12.022
 29. Coughlin SM, Emmerton-Coughlin HM, Malthaner R. Management of chest tubes after pulmonary resection: a systematic review and meta-analysis. *Can J Surg.* 2012;55(4):264-270. doi:10.1503/cjs.001411
 30. Anderson BL, Abdalla R, Frame SB, Casey MT, Gould H, Maull KI. Tube thoracostomy for occult pneumothorax: a prospective randomized study of its use. *J Trauma.* 1993;35(5):726-729. doi:10.1097/00005373-199311000-00013
 31. Novoa NM, Jiménez MF, Varela G. When to remove a chest tube. *Thorac Surg Clin.* 2017;27(1):41-46. doi:10.1016/j.thorsurg.2016.08.007
 32. Cerfolio RJ, Bryant AS. Results of a prospective algorithm to remove chest tubes after pulmonary resection with high output. *J Thorac Cardiovasc Surg.* 2008;135(2):269-273. doi:10.1016/j.jtcvs.2007.08.066
 33. Younes RN, Gross JL, Aguiar S, Haddad FJ, Deheinzelin D. When to remove a chest tube? a randomized study with subsequent prospective consecutive validation. *J Am Coll Surg.* 2002;195(5):658-662. doi:10.1016/S1072-7515(02)01332-7
 34. Grodzki T. Prospective algorithm to remove chest tubes after pulmonary resection with high output—is it valid everywhere? *J Thorac Cardiovasc Surg.* 2008;136(2):536. doi:10.1016/j.jtcvs.2008.04.017
 35. French DG, Dilena M, LaPlante S, et al. Optimizing postoperative care protocols in thoracic surgery: best evidence and new technology. *J Thorac Dis.* 2016;8(suppl 1):S3-S11.
 36. Platnick C, Witt CE, Pieracci FM, et al. Beyond the tube: can we reduce chest tube complications in trauma patients? *Am J Surg. Am J Surg.* 2021;222(5):1023-1028. doi:10.1016/j.amjsurg.2021.04.008
 37. Pieracci FM, Burlew CC, Spain D, et al. Tube thoracostomy during the COVID-19 pandemic: guidance and recommendations from the AAST Acute Care Surgery and Critical Care Committees. *Trauma Surg Acute Care Open.* 2020;5(1):e000498. doi:10.1136/tsaco-2020-000498
 38. Hernandez MC, El Khatib M, Prokop L, Zielinski MD, Aho JM. Complications in tube thoracostomy: systematic review and meta-analysis. *J Trauma Acute Care Surg.* 2018;85(2):410-416. doi:10.1097/TA.0000000000001840
 39. Dhanasopon AP, Zurich H, Preda A. Chest tube drainage in the age of COVID-19. *Physician Assist Clin.* 2021;6(2):261-265. doi:10.1016/j.cpha.2020.11.011
 40. Gedik İE, Alar T. Protective measures undertaken during chest tube thoracostomy in COVID-19 outbreak. *Indian J Thorac Cardiovasc Surg.* 2020;37(2):1-4.
 41. Hallifax RJ, McKeown E, Sivakumar P, et al. Ambulatory management of primary spontaneous pneumothorax: an open-label, randomised controlled trial. *Lancet.* 2020;396(10243):39-49. doi:10.1016/S0140-6736(20)31043-6
 42. Brown SGA, Ball EL, Perrin K, et al; PSP Investigators. Conservative versus interventional treatment for spontaneous pneumothorax. *N Engl J Med.* 2020;382(5):405-415. doi:10.1056/NEJMoa1910775
 43. Zhang J-T, Dong S, Chu X-P, et al. Randomized trial of an improved drainage strategy versus routine chest tube after lung wedge resection. *Ann Thorac Surg.* 2020;109(4):1040-1046. doi:10.1016/j.athoracsur.2019.11.029

JAMA Surgery—The Year in Review, 2022

Melina R. Kibbe, MD

2022 was a year associated with tremendous accomplishments for *JAMA Surgery*. First, as evidence of the high-quality scientific publications in *JAMA Surgery*, the impact factor rose from 14.8 to 16.7. This remarkable achievement reflects the hard work of the journal's authors, peer reviewers, and editorial team. The impact factor, along with other important metrics, continues to position *JAMA Surgery* as the number 1 ranked surgery journal in the world.

In 2022, the acceptance rate for all article types was 19%; for Original Investigations, 8%; and for Research Letters, 17%. The journal's most popular articles by views and downloads, news and social media coverage, and citations are listed in the Table.¹⁻⁹ The web and social media presence for *JAMA Surgery* continues to be strong under the leadership of

Amalia L. Cochran, MD, the Web and Social Media Editor. More than 4.6 million articles were viewed and downloaded from the journal website in 2022. The journal's electronic table of contents is delivered each week to more than 126 000 individuals. We currently have 47 500 Twitter followers, which represents an 11.6% increase in 2022, and 27 161 Facebook followers, which represents a 0.3% increase in 2022 (Table). Thus, between the electronic table of contents, visits to the journal website, social media reach, and print distribution, *JAMA Surgery* reaches more than 130 000 individuals weekly.

JAMA Surgery continues to promote the work of authors through additional outlets. *JAMA Surgery* publishes author interview podcasts¹⁰ each month under the direction of Dr Cochran, who brings a wonderful level of insight into the interview process with the authors. Articles published in *JAMA Surgery* had extensive press coverage, with 8179 media mentions in 2022 in outlets such as *The New York Times*, *Wall Street Journal*, *USA Today*, *CNN*, *NPR*, and *Forbes*. In recognition of the press coverage, web, and social media support, articles in *JAMA Surgery* have done well with Altmetric scores (measures of news and social media attention). *JAMA Surgery*

Table. JAMA Surgery Statistics for 2022

Characteristic ^a	Result
Manuscript data	
All manuscripts received	2446
Research manuscripts received ^b	1933
Acceptance rate, %	
Overall	19
Research	9
Original Investigations	
Received, No.	1701
Acceptance rate, %	8
Research Letters	
Received, No.	232
Acceptance rate, %	17
Viewpoints	
Received, No.	130
Acceptance rate, %	24
Manuscripts sent for external peer review, %	25
Peer reviewers, No.	436
Receipt to first decision without peer review, median, d	11
Receipt to first decision with peer review, median, d	39
Peer reviewer turnaround, median, d	10
Acceptance to publication, median, d	84
Receipt to publication, median, d	133
2021 Journal impact factor	16.7
Information dissemination data	
Recipients of electronic table of contents per week	126 098
Views/downloads per year, million	4.6
Media mentions	8179
Social media followers	74 661
Twitter	47 500
Facebook	27 161
LinkedIn	2813

(continued)

Table. JAMA Surgery Statistics for 2022 (continued)

Characteristic ^a	Result
Top 3 articles by views/downloads	
1. Gao et al, ¹ Effect of Early vs Late Supplemental Parenteral Nutrition in Patients Undergoing Abdominal Surgery: A Randomized Clinical Trial	28 050
2. Rohatgi et al, ² Perioperative Cardiovascular Considerations Prior to Elective Noncardiac Surgery in Patients With a History of COVID-19	27 956
3. Anderson et al, ³ Comprehensive Review of Chest Tube Management: A Review	21 792
Top 3 articles by Altmetric score	
1. Gill et al, ⁴ Population-Based Estimates of 1-Year Mortality After Major Surgery Among Community-Living Older US Adults	769
2. Burns et al, ⁵ Association of Anesthesiologist Staffing Ratio With Surgical Patient Morbidity and Mortality	538
3. Forbes et al, ⁶ Uterine Transplant—Progress, but Concerns Remain	529
Top 3 articles by Web of Science citations	
1. Markmann et al, ⁷ Impact of Portable Normothermic Blood-Based Machine Perfusion on Outcomes of Liver Transplant: the OCS Liver PROTECT Randomized Clinical Trial	34
2. Lim et al, ⁸ Survival After Hyperthermic Intraperitoneal Chemotherapy and Primary or Interval Cytoreductive Surgery in Ovarian Cancer: A Randomized Clinical Trial	18
3. Rosen et al, ⁹ Biologic vs Synthetic Mesh for Single-stage Repair of Contaminated Ventral Hernias: A Randomized Clinical Trial	16

^a Data based on all manuscripts submitted, including research, review and education, opinion, and letters.

^b Includes Original Investigations and Research Letters.

published 4 of the top 5 and 34 of the top 50 articles by Altmetric score among surgery journals in 2022.

In 2022, *JAMA Surgery* published the fourth series of short educational articles intended to help surgeons who conduct randomized clinical trials and interpret the findings of the trials. The series, entitled “Guide to Statistics and Methods: Randomized Clinical Trials in Surgery,” is an 11-part series intended to address the critical aspects of managing randomized clinical trials.¹¹ Earlier Guide to Statistics and Methodology series include Reporting Guidelines published in 2021, Health Services Research Methodology published in 2020, and the Practical Guide to Surgical Data Sets published in 2018.¹²⁻¹⁴ All of these Guides to Statistics and Methods series can be found at <https://jamanetwork.com/journals/jamasurgery/pages/statistics-and-methods>.

In 2022, we also welcomed our new editor in chief of the JAMA Network, Kirsten Bibbins-Domingo, PhD, MD, MAS.

We look forward to the impact Dr Bibbins-Domingo will have on the science published across the JAMA Network journals. Additionally, *JAMA Surgery* welcomed our inaugural Deputy Editor for Diversity, Equity, and Inclusion, Leah M. Backhus, MD, MPH. The creation of this position is part of many initiatives related to diversity, equity, and inclusion across the JAMA Network.

Overall, 2022 was a good year for *JAMA Surgery*. I thank the readers, authors, peer reviewers,¹⁵ and editorial board for contributing to the journal. Through your support, we aim to fulfill our mission to promote the art and science of surgery by publishing relevant peer-reviewed research to assist surgeons in optimizing patient care and to serve as a forum for the discussion of issues pertinent to surgery, such as diversity, equity, and inclusion; the education and training of the surgical workforce; quality improvement; and the ethics and economics of health care delivery.

ARTICLE INFORMATION

Author Affiliations: Editor, *JAMA Surgery*; University of Virginia School of Medicine, Charlottesville; UVA Health, Charlottesville, Virginia; Department of Surgery, University of Virginia, Charlottesville; Department of Biomedical Engineering, University of Virginia, Charlottesville.

Corresponding Author: Melina R. Kibbe, MD, University of Virginia School of Medicine, 1415 Jefferson Park Ave, McKim Hall 3009, PO Box 800793, Charlottesville, VA 22908-0793 (melinakibbe@virginia.edu).

Published Online: March 22, 2023.
doi:10.1001/jamasurg.2023.0248

Conflict of Interest Disclosures: None reported.

REFERENCES

- Gao X, Liu Y, Zhang L, et al. Effect of early vs late supplemental parenteral nutrition in patients undergoing abdominal surgery: a randomized clinical trial. *JAMA Surg*. 2022;157(5):384-393. doi:10.1001/jamasurg.2022.0269
- Rohatgi N, Smilowitz NR, Reejhsinghani R. Perioperative cardiovascular considerations prior to elective noncardiac surgery in patients with a history of COVID-19. *JAMA Surg*. 2022;157(3):187-188. doi:10.1001/jamasurg.2021.6953
- Anderson D, Chen SA, Godoy LA, Brown LM, Cooke DT. Comprehensive review of chest tube

management: a review. *JAMA Surg*. 2022;157(3):269-274. doi:10.1001/jamasurg.2021.7050

4. Gill TM, Vander Wyk B, Leo-Summers L, Murphy TE, Becher RD. Population-based estimates of 1-year mortality after major surgery among community-living older US adults. *JAMA Surg*. 2022;157(12):e225155. doi:10.1001/jamasurg.2022.5155

5. Burns ML, Saager L, Cassidy RB, Mentz G, Mashour GA, Khetarpal S. Association of anesthesiologist staffing ratio with surgical patient morbidity and mortality. *JAMA Surg*. 2022;157(9):807-815. doi:10.1001/jamasurg.2022.2804

6. Forbes RC, Karp S. Uterine transplant—progress, but concerns remain. *JAMA Surg*. 2022;157(9):797-798. doi:10.1001/jamasurg.2022.2652

7. Markmann JF, Abouljoud MS, Ghobrial RM, et al. Impact of portable normothermic blood-based machine perfusion on outcomes of liver transplant: the OCS Liver PROTECT randomized clinical trial. *JAMA Surg*. 2022;157(3):189-198. doi:10.1001/jamasurg.2021.6781

8. Lim MC, Chang SJ, Park B, et al; HIPEC for Ovarian Cancer Collaborators. Survival after hyperthermic intraperitoneal chemotherapy and primary or interval cytoreductive surgery in ovarian cancer: a randomized clinical trial. *JAMA Surg*. 2022;157(5):374-383. doi:10.1001/jamasurg.2022.0143

9. Rosen MJ, Krpata DM, Petro CC, et al. Biologic vs synthetic mesh for single-stage repair of contaminated ventral hernias: a randomized clinical trial. *JAMA Surg*. 2022;157(4):293-301. doi:10.1001/jamasurg.2021.6902

10. *JAMA Surgery* author interviews. *JAMA Surgery*. Accessed January 23, 2023. <https://jamanetwork.com/journals/jamasurgery/pages/jama-surgery-author-interviews>

11. Itani KMF, Kibbe MR. Clinical trials design, scientific rigor, and higher-level evidence in surgery. *JAMA Surg*. 2022;157(12):1078-1079. doi:10.1001/jamasurg.2022.4880

12. Brooke BS, Ghaferi AA, Kibbe MR. Effective use of reporting guidelines to improve the quality of surgical research. *JAMA Surg*. 2021;156(6):515-516. doi:10.1001/jamasurg.2021.0519

13. Ghaferi AA, Haider AH, Kibbe MR. Maximizing the impact of surgical health services research: the methodology toolbox. *JAMA Surg*. 2020;155(3):190-191. doi:10.1001/jamasurg.2019.5479

14. Haider AH, Bilimoria KY, Kibbe MR. A checklist to elevate the science of surgical database research. *JAMA Surg*. 2018;153(6):505-507. doi:10.1001/jamasurg.2018.0628

15. *JAMA Surgery* peer reviewers in 2022. *JAMA Surg*. Published online March 22, 2023 doi:10.1001/jamasurg.2023.0317