Lesion Detectability in Contrast-Enhanced bCT using Model Observers

Su Hyun Lyu, Andrew M. Hernandez, Craig K. Abbey, John M. Boone
Departments of Radiology & Biomedical Engineering, University of California Davis

INTRODUCTION

- Breast CT (bCT) is a tomographic x-ray based imaging technique that generates 3D images of the breast.
- Since 2005, our bCT protocol has involved the intravenous injection of an iodinated contrast agent to improve the visualization of malignant lesions.
- Contrast-enhanced breast CT (CE-bCT) is being evaluated as a tool for screening in high-risk populations, for diagnostic breast exams, for cancer staging, targeting, and more.

OBJECTIVES

- To quantify improvement in lesion detectability due to contrast enhancement across lesion diameter, section thickness, view plane, and breast density.
- To optimize contrast imaging protocols for lesion detection.

METHODS

STUDY OVERVIEW

1) Mathematically generate spherical breast lesions and insert them into patient bCT images.
2) Use a pre-whitened matched filter (PWMF) model observer to analyze lesion detectability.

RELATIONSHIP BETWEEN [I] AND HU

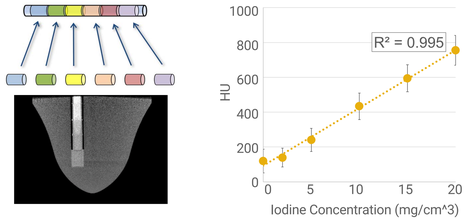

- The relationship between [I] and HU was measured using an iodine rod phantom placed in a polyethylene breast phantom and scanned on a bCT system. R^2 value of 0.995 was found.

METHODS

SYNTHETIC LESION INSERTION

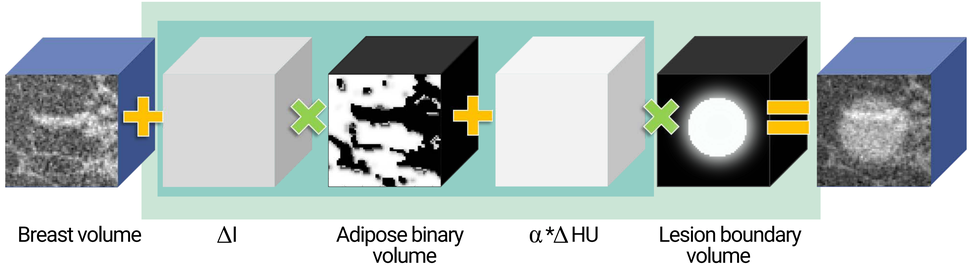

Alpha	Lesion Diameter (mm)	Section thickness (mm)	Plane
0.00	1	0.4	Coronal
0.25	3	1.2	Axial
0.50	5	1.9	
0.75	9	3.5	
1.00	11	5.8	
	15	19.8	

Table 1) Different combinations of alpha, lesion diameter, section thickness, and view plane were used to mathematically generate synthetic lesion images.

NON-CON LESIONS

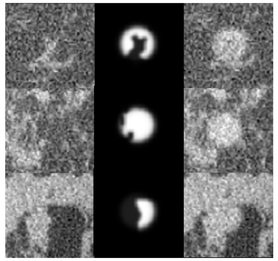

CONTRAST LESIONS

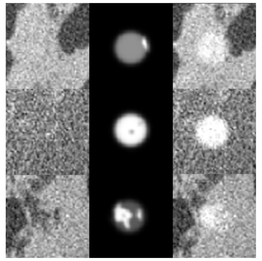

MODEL OBSERVER for a signal known exactly task

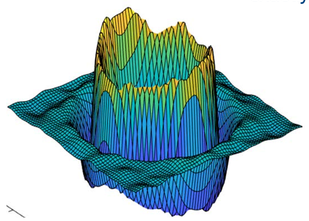

Surface contouring of PWMF

- 200 lesions were inserted at random locations into each bCT image (N = 139) to compute a mean signal profile for each combination of parameters.
- A PWMF was generated based on the mean signal profile, and then used to compute a decision variable.
- ROC curve analysis was used to compute the AUC, a measure of detection performance. AUC was averaged across all 139 bCT images.

RESULTS

EFFECTS OF SECTION THICKNESS

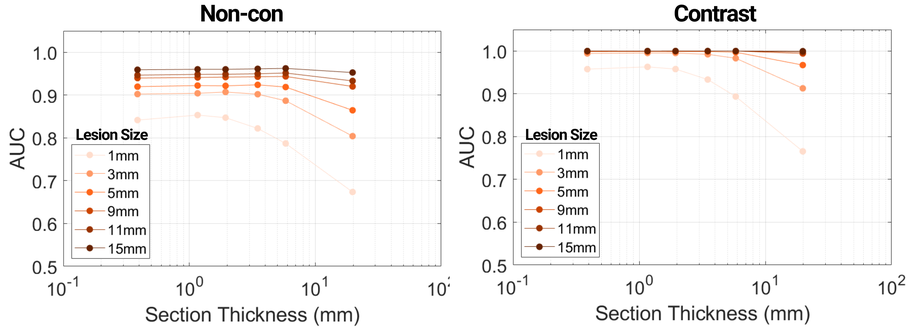

EFFECTS OF BREAST DENSITY

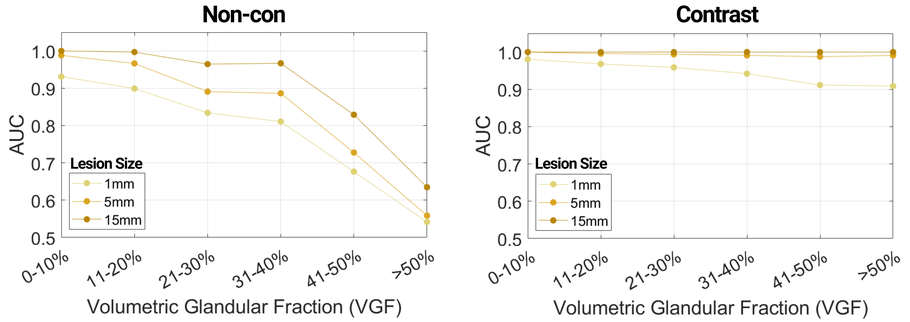

CONCLUSIONS

- Contrast enables detection of lesions > 1mm ~100% of the time across all section thicknesses.
- The optimal section thickness for detecting smaller lesions is ~1.5x the lesion diameter.
- In denser breasts, contrast improves lesion detectability by 25-35% on average.
  - Contrast can "correct" for breast density.

ACKNOWLEDGMENTS

- NIH R01 CA 181081
- NIH R01 CA 214515 (via Stanford Research Institute)
- NIH R01 EB 025829 (via UCSB)

CONTACT

Sunny Lyu
slyu@ucdavis.edu